



DATE PRESENTING CLINICAL SIGNS

1.9.26

History: Recheck echo. Progressive, now grade 3/6 heart murmur. Weight loss and inappetence. Early stage 2 CKD. Concern for intestinal disease with d mild LP IBD diagnosed in 2024. Also, a 1cm hypoechoic nodule seen on the liver in 2024. Assess prior to anesthesia.

PATIENT

Mimi Peltier

-Pertinent abnormal PE/Chem/CBC/UA Results: creat 1.5, urine sg 1.014.
-Current medications: Cobalequin SID.
-Sedation used: Not required to complete full diagnostic ultrasound.
-Pertinent previous ultrasound results (6/2025 CVCA): DRVOTO. Mild TR. Overall normal.
-STAT: Not requested.

SPECIES

Feline

-Imaging performed by: Stephanie Warga RDCS, RVT.

BREED

DSH

ECHOCARDIOGRAM FINDINGS

2D, m-mode, color flow and doppler imaging is available. The left ventricular wall is normal in dimension. There is a diffusely hyperechoic endocardium consistent with fibrosis and remodeling. The papillary muscles appear mildly remodeled. The left atrium is normal in size. The right atrium is normal in size. The right ventricle appears normal. The tricuspid valve appears normal in structure and mobility. Trace tricuspid regurgitation. The mitral valve is normal in structure and mobility. No mitral regurgitation. Blood flow through the RVOT is mildly elevated in velocity, likely secondary to tachycardia creating a benign outflow tract obstruction. Blood flow through the LVOT appears normal with no evidence of obstruction. No evidence of cardiac tumors or metastatic lesions on this scan. No pericardial or pleural effusion.

AGE

11.11.11

CARDIAC CHART

WEIGHT

6.5lbs

INTERPRETED BY

Maggie Machen Lamy,
DVM, DACVIM
(Cardiology)

HOSPITAL NAME

Cat Sense Feline
Hospital

REFERRING VET

Dr. Sinclair

INVOICE

46374

FELINE CARDIAC PARAMETERS	BODY WEIGHT (kg)	HR (BPM)	IVSd (cm) (Moise, Pipers)	LVIDd (cm) (Moise, Pipers)	LVWd (cm) (Moise, Pipers)	FS (%)	EF (%)
NORMAL PARAMETER	-----	150-240	3.5-0.55	<2 (mean 1.5)	3.5-0.55	35-67	80-100
PATIENT	2.9	NM	0.49	1.1	0.42	45	82
FELINE CARDIAC PARAMETERS	LA/AO (Boon)	LA/AO HEART BASE (Swe) (Abbott)	LA 2D short axis Base view (cm) (Abbott)		LVOT VEL (m/s)	RVOT VEL (m/s)	E max (m/s)
NORMAL	<1.5	<1.3	<1.2		<1.6	<1.3	<0.9
PATIENT	NM	1.1	1.0		0.95	1.6	NM

Adapted from June Boon, Veterinary Echocardiography, 1998
Abbott J & MacLean H JVIM 2006;20: 111-119, Moise et al. Am J Vet Res 47:1476, 1986. Pipers et al. Am J Vet Res 40:882, 1979.

INTERPRETATION OF THE FINDINGS & FURTHER RECOMMENDATIONS

The only cause of a murmur identified is a heart rate dependent flow obstruction through the right ventricular outflow tract (DRVOTO), which is a physiologic finding (i.e. benign and of little clinical significance). This type of flow murmur will wax and wane secondary to tachycardia and volume changes. There is mild LV remodeling and fibrosis, which may be indicative of early pathology or simply represent a normal age-related variant. Regardless, the left atrial dimension is normal, and there

is minimal risk for complication at this time. Serial echocardiography will be necessary to determine progression and clinical relevance in the future. Compared to prior report, findings are similar to the prior evaluation, which is good news.

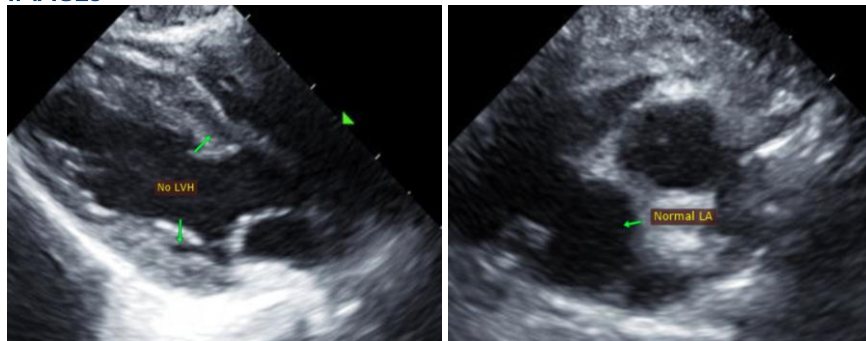
Given these findings, no medications are indicated at this time. Prognosis is open.

If needed, the risk for general anesthesia is low. Even without significant pathology, with ventricular remodeling and diastolic stiffening there is a mildly elevated risk for fluid overload. Judicious IV fluid use is recommended. Additionally, a screening blood pressure is recommended in any cat prior to general anesthesia.

Risk for complication with steroid or fluid use typically follows LA dilation, which in this case is low. That said, any cat can experience acute intolerance and monitoring for this phenomenon is always advised (a change in RR/RE, particularly during the initiation phase).

Recommend recheck echocardiogram in 1 year to assess for progression or development of disease the pre-existing murmur may mask.

IMAGES



The information and recommendations provided are based on the images presented by the referring veterinarian. No evaluation can be communicated regarding pathology that was not visible in the image/video clips provided.

Thank you for this referral. This report was generated using transcription software, and minor dictation errors may be present. If the clinical or image interpretation does not parallel your findings or if I can be of any further assistance, please contact me.

Maggie Machen Lamy, DVM
Diplomate of the American College of Veterinary Internal Medicine (Cardiology)
info@sonopath.com